



## Translation of a spinal bone cement product from bench to bedside

Fei Feng<sup>a,1</sup>, Mengmeng Chen<sup>a,1</sup>, Xuan Wang<sup>b</sup>, Hongwei Zhang<sup>b</sup>, Hongtao Nie<sup>b,\*\*</sup>, Hai Tang<sup>a,\*</sup>

<sup>a</sup> Department of Orthopedics, Beijing Friendship Hospital, Capital Medical University, No. 95, Yong An Rd, Xi Cheng District, Beijing, 100050, China

<sup>b</sup> Beijing Bonsci Technology Co Ltd, No.100, 6th Kechuang Street, Beijing Economic and Technological Development Area, Beijing, 100176, China

### ARTICLE INFO

#### Keywords:

Bone cement  
Spine  
Translational research  
Vertebroplasty  
Kyphoplasty  
Safety and efficacy

### ABSTRACT

Spinal acrylic bone cements (ABCs) are used clinically for percutaneous vertebroplasty (PVP) and kyphoplasty (PKP) to treat osteoporotic vertebral compression fractures. Product translation of spinal ABC products followed the design control processes including design verification and validation. The bench to bedside translation of the first Chinese spinal ABC product (Alliment®, namely Alliment Cement) approved by National Medical Products Administration of China was investigated and another commercial product served as the control (Osteopal®V, namely Osteopal V Cement). Results of non-clinical bench performance verification tests of compression, bending and monomer release showed that the newly marketed Alliment Cement is similar to the Osteopal V Cement with properties of both meeting the criteria specified by standards. The Alliment Cement demonstrated good biocompatibility during the 26 weeks' bone implantation test. Porcine cadaver validation tests further revealed that the Alliment Cement satisfied the needs for both PVP and PKP procedures. A post-approval, retrospective clinical investigation further demonstrated the safety and efficacy of the Alliment Cement, with a significant reduction of pain and the improved stability of the fractured vertebral bodies. A successful translation of biomaterial medical products needs close collaborations among academia, industry, healthcare professionals and regulatory agencies.

### 1. Introduction

Acrylic bone cement (ABC) was invented in the 1950s along with the total hip arthroplasty [1–3]. Although there were independent efforts towards the development of acrylic cements for orthopedic applications, the idea of using ABC to fix hip implants was generally accredited to the collaboration between a biomaterials scientist, Dennis C. Smith and the father of modern joint arthroplasty, Sir John Charnley [1]. With the fast development of total joint arthroplasty in the second half of the 20th Century, research and product development of ABCs for joint replacements had been a hectic area in the early stage of biomaterials field [4–8]. For the pioneering research and clinical applications of ABCs in joint arthroplasty, biomaterials science and engineering projects were conducted with a focus on the investigation of relationships among formulation, processing, structure and properties [9–12]. Several ABC products were developed and marketed in both Europe and America, even before the establishment of the Medical Device Amendment in

1976 by the US Food and Drug Administration. With demonstrated clinical safety and effectiveness, ABCs for joint replacements are a class of the most successful implantable biomaterials [1,3].

The development and commercialization of antibiotic-loaded acrylic bone cement (ALBC) products is a milestone achievement for both ABCs and biomaterials in general [13–17]. In the 1970s, antibiotics were frequently formulated on site during clinical applications of ABC in total joint replacements. As a result, commercial ALBC products were developed with the addition of gentamicin or vancomycin or even both to ABCs. In the history of implantable medical devices, ALBC products are one type of the earliest combination products, even before the concept was proposed and later such products were regulated as a novel class of medical products. Based on recent reports, ALBCs account for the majority of clinical usage of ABCs in joint arthroplasty [18].

Between the mid-1980s and 2000s, the clinical development of percutaneous vertebroplasty (PVP) and kyphoplasty (PKP) for the treatment of osteoporotic vertebral compression fractures (OVCF)

Peer review under responsibility of KeAi Communications Co., Ltd.

\* Corresponding author.

\*\* Corresponding author.

E-mail addresses: [tao.hong@bonscimed.com](mailto:tao.hong@bonscimed.com) (H. Nie), [tanghai@ccmu.edu.cn](mailto:tanghai@ccmu.edu.cn) (H. Tang).

<sup>1</sup> These authors contributed equally.

<https://doi.org/10.1016/j.bioactmat.2021.08.011>

Received 1 July 2021; Received in revised form 1 August 2021; Accepted 9 August 2021

Available online 14 August 2021

2452-199X/© 2021 The Authors. Publishing services by Elsevier B.V. on behalf of KeAi Communications Co. Ltd. This is an open access article under the CC

BY-NC-ND license (<http://creativecommons.org/licenses/by-nc-nd/4.0/>).

initiated the research and development of spinal ABC products [19–22]. Compared to the ABCs that are used to physically fix joint implants to bone tissues, spinal ABCs for both PVP and PKP procedures are intended to fill and stabilize the fractured or damaged vertebral body [23–25]. The differences in terms of intended uses and surgical/anatomic sites between spinal and joint ABCs bring different requirements for their performance, surgical techniques as well as surgical instruments. For example, the requirements of dough time and radiopacity are different between spinal and joint ABCs. As a result, the formulations and compositions of spinal ABCs are quite different from those of joint ABCs.

Similar to ABCs for joint replacements, spinal ABCs are also composed of powder and liquid components [26,27]. The powder component is typically composed of acrylic polymer (e.g., polymethylmethacrylate, PMMA), radiopacifier (e.g., barium sulfate, BaSO<sub>4</sub>), and initiator (e.g., benzoyl peroxide, BPO) [26,27]. The liquid component mainly contains monomer of methyl methacrylate (MMA), activator of N, N-dimethyl-p-toluidine, DMPT and stabilizer of hydroquinone, HQ [26,27]. However, the specific compositions are different between spinal and joint ABCs. For example, in order to satisfy imaging requirements, spinal ABCs have more radiopacifier than joint ABCs [26, 27]. A few spinal ABC products have been marketed in Europe, US, and later in China with the market growth of both PVP and PKP procedures [26,27].

Translation of an ABC product, as of other medical devices, takes multiple phases which are associated with the product design control processes [28]. The starting point of a targeted commercial product is always a clear and logical design plan, with the initial phase of product concept and proof-of-concept. Then, the phase of identification of user needs which include but not limited to clinical needs is critical to move forward the product development process. Next, these user needs are translated to design input, then further derive to design output through various design processes. During the phase of design verification, it is important to make sure that the design output meets the design input. Furthermore, during the phase of design validation, which overlaps the phase of design transfer (i.e., the phase of manufacturing the product per established and maintained production specifications and procedures), the designed and manufactured final products must satisfy the specified user needs. Design reviews are conducted throughout the design control process of a medical device product to ensure that the process is documented, comprehensive, and systematic.

The objective of this research is to present the important process and results for the bench-to-clinic translation of the first Chinese spinal ABC product (Alliment®, i.e., Alliment Cement) approved by the National Medical Products Administration of China (NMPA). Firstly, a series of non-clinical performance bench tests including compressive and flexural as well as monomer release tests were conducted per relevant standards. Secondly, the preclinical biocompatibility evaluation was conducted with a focus on one of the most important tests, i.e., the long term bone implantation. Thirdly, product validation tests with porcine cadavers were executed to demonstrate that the Alliment Cement as well as its surgical instruments for both PVP and PKP could satisfy the user needs. Finally, a post-approval, retrospective clinical investigation was reported to evaluate the safety and efficacy of the Alliment Cement. A currently-marketed spinal ABC product (Osteopal®V, i.e., Osteopal Cement) was used as a control.

## 2. Materials and methods

### 2.1. Materials

The Alliment Cement investigated in this study was manufactured and marketed by Beijing Bonsci Technology Co. Ltd. (Alliment® Spinal Bone Cement, Model: S-MV-20). The product has both powder and liquid components. The powder mainly contains polymethyl methacrylate copolymer, barium sulfate and benzoyl peroxide. The liquid mainly contains MMA monomer, DMPT and HQ. The product is

sterilized and packaged for one-time use only. The liquid in the ampoule is sterilized by aseptic filtration. The blister packaging of the ampoule is then sterilized by ethylene oxide. The powder and its packaging are sterilized by gamma irradiation.

The control Osteopal V Cement in this study was manufactured and marketed by Heraeus (Osteopal®V). The powder ingredients are poly (methyl acrylate, methyl methacrylate), zirconium dioxide, benzoyl peroxide, and colorant E 141. The monomer liquid ingredients are MMA, DMPT, HQ, and colorant E 141 [29]. The Osteopal V Cement powder and its polyethylene pouch as well as the monomer ampoule blister are sterilized by ethylene oxide. The monomer liquid has been sterilized by filtration.

### 2.2. Test methods

Before all non-clinical bench performance tests and porcine cadaver tests, the mixing equipment and the bone cement products were kept at  $(23 \pm 2) ^\circ\text{C}$  and relative humidity (RH) of  $50 \pm 10\%$  for at least 2h. Student-t test was used for statistical analysis with a level of  $p < 0.05$  for a significant difference.

#### 2.2.1. Compressive test

After mixing the bone cements according to the ISO 5833 [30], five cylinder specimens with a height of  $12 \pm 0.1$  mm and a diameter of  $6 \pm 0.1$  mm were prepared. Compressive tests were performed according to the ISO 5833 [30] with an electronic universal testing machine (SanSiZongHeng, Model UTM5105X, Shenzhen, China) and a crosshead rate of 25.4 mm/min test until the sample breaks.

#### 2.2.2. Flexural test

After mixing the bone cements according to the ISO 5833 [30], five rectangular bars with a length of  $75 \pm 0.1$  mm, a width of  $10 \pm 0.1$  mm, a thickness of  $3.3 \pm 0.1$  mm were prepared. Flexural tests were performed according to the ISO 5833 [30] with an electronic universal testing machine (SanSiZongHeng, Model UTM5105X, Shenzhen, China) and a crosshead rate of 5 mm/min test until the sample breaks.

#### 2.2.3. Monomer release test

Test specimens were prepared according to ASTM-F451 [31]. First, rectangular bars were prepared the same as those for flexural tests. Then, the bars were cut to smaller rectangular specimens with a size of  $3 \times 5 \times 15$  mm and weighed separately. Five specimens were prepared for each of the following time points (0, 1, 3, 7, 14 d) to ensure that five extraction liquid samples can be obtained at each time point for monomer release analysis.

According to ASTM-F451 [31], standard solutions of MMA with concentrations of 20, 60, 100, 300, 450  $\mu\text{g/ml}$  were prepared. Then, as-prepared five pieces of bone cement specimens were placed in sample bottles of 5 ml purified water which meets the specification in Chinese Pharmacopoeia 2020, then sealed and placed in a water bath at  $37 ^\circ\text{C}$ . Each 0.2 ml of the eluent in the sample bottles was taken out at different time intervals (0, 1, 3, 7, and 14 d), respectively. The sample bottles were sealed after sampling. A gas chromatograph (Agilent Technologies Gas Chromatograph, Model 7820A, California, USA) was used to characterize the release of MMA monomer in the eluent at the above time intervals, and the results were reported as  $\mu\text{g MMA/g bone cement}$  [32]. The chromatographic column was phenyl methyl type (HP-5, length:30 m; internal diameter: 0.32 mm; film thickness: 0.25  $\mu\text{m}$ ) and the detector was flame ionization detector (temperature:  $300 ^\circ\text{C}$ ). Nitrogen was used as carrier gas.

#### 2.2.4. Biocompatibility: bone implantation test

The cylinder test specimens with a diameter of 2 mm and a length of 6 mm were prepared according to ISO 10993-6. The control specimens of the same size were made of implantable ultra-high molecular weight polyethylene (UHMWPE) that were prepared and provided to Beijing

Bonsci by Beijing KeYiBangEn Medical Device Co. Ltd. The following biocompatibility test was performed and reported to Beijing Bonsci by Shanghai Biomaterials Research and Testing Center according to ISO 10993–6 and the animal experiments were also approved by the Animal Care and Use Committee.

24 healthy New Zealand rabbits (four of which were extra spare) were used for the test. The animals weighted between 2.1 kg and 2.6 kg, with half male and the other half female rabbits. According to the ISO 10993–6 [33], the tibial drilling method was used. The animals were anesthetized via ear vein with 3.0% sodium pentobarbital (dose 1.0 ml/kg animal). The surgeries were conducted following the procedures with skin preparation, disinfection and draping of the medial tibia. Then, the tibial was exposed after the skin incision and subcutaneous tissue dissection. Two cylindrical cavities in each tibia were created with a low-speed drill. Then the cavities were washed with saline. The cavities have a diameter of about 2 mm and spacing in between about 10 mm. One tibia was implanted with bone cement specimens and the other tibia was implanted with control of UHMWPE. After implantation, the muscle, fascia, and skin were gradually sutured.

After 1, 4, 12, and 26 weeks, the bone tissues containing the implanted samples were dissected, fixed in 10% formaldehyde solution, and then decalcified with a decalcification solution containing 7% crystalline aluminum chloride, 4.76% formic acid and 3.15% hydrochloric acid. After a series of ethanol dehydration, xylene treatment, and paraffin embedment, the tissues were sectioned via long axis that is vertical to the implants. An optical microscope was used to observe and image the fixed tissue samples after HE staining. The test group (i.e., Alliment Cement) and the control group (i.e., UHMWPE) were compared, and their histopathological responses were graded and recorded.

Conditions of the implants and characteristics and degree of tissue reactions were visually observed. The histological results after bone implantation were reported by observations of inflammatory response, the fibrous tissue cavity, and the residual material at the implantation sites.

### 2.2.5. Porcine cadaver study

Instruments and porcine vertebral cadaver were prepared before the cadaver study. Balloon kyphoplasty kit, inflatable bone tamp, mixing bowl, stirring bar were all provided by the Beijing Bonsci Technology Co., Ltd. The cadaver study was performed with the following steps. At first, working channels and cavities of the porcine spine were created using a balloon kyphoplasty kit and an inflatable bone tamp, respectively. Then Alliment Cement was prepared after mixing powder and liquid in the mixing bowl with a stirring bar. After the cement was mixed well, it was transferred to cement filler device via a syringe. The cement was injected into the vertebral body cavities created by the inflatable bone tamp. Finally, the bone cement filler device and cannula were removed. The porcine vertebral body was dissected to observe the distribution of the injected cement.

## 2.3. Clinical investigation

Both the investigated Alliment Cement and the control, Ostopal V Cement went through separate clinical trials before their regulatory registration and approval. This post-approval study was a single-center, retrospective cohort study to further investigate the safety and efficacy of both commercial products. The study was reviewed and approved by the Ethical Committee of Beijing Friendship Hospital. Informed consent form of each enrolled patient was signed by the patient or relatives. From September 2019 to June 2020, all patients who underwent PVP in our hospital due to osteoporotic thoracolumbar compression fractures were considered to be included in the study.

### 2.3.1. Inclusion criteria

1. Definite diagnosis with fresh thoracolumbar compression fracture through MRI or radionuclide bone scan;
2. Type A1 based on AO thoracolumbar fracture classification;
3. PVP procedures with PMMA bone cement;
4. Vertebrae fractures caused by low-energy trauma.

### 2.3.2. Exclusion criteria

1. Vertebrae fractures complicated with vertebral hemangioma and spinal metastases;
2. Malignant tumor history;
3. Treatment with resorbable bone fillers;
4. More than three vertebrae fractures;
5. Neurological symptom accompanied by severe spine degenerative disease;
6. Incomplete clinical and radiological data.

### 2.3.3. Patients groups

According to the injected bone cement, the included patients were divided into two groups. Group A was the Chinese medium-viscosity bone cement group (Alliment®, Beijing Bonsci Technology Co. Ltd.), and group B was the German high-viscosity bone cement group (Osteopal®V, Heraeus) [34]. The patients' basic information of both groups were recorded including age, sex, BMD, body mass index (BMI), and preoperative serum albumin level. Pre & post-operative thoracolumbar spine X-rays and corresponding segmental computed tomography (CT) were recorded for all included patients.

### 2.3.4. Surgical procedures

All patients were placed in the prone position and the responsible segment and puncture point were determined using X-ray fluoroscopy. 2% lidocaine was used for local anesthesia along the puncture path. The puncture was performed under X-ray monitoring, and the position of the puncture needle was adjusted according to the fluoroscopy results until a satisfying position was achieved. Then the puncture needle was pulled out and the working cannula was inserted. Next, bone cements were prepared after mixing the powder and liquid thoroughly.

After mixing, the bone cement was injected into fractured vertebrae. During the injection process, surgeons should watch out for bone cement leakage. The cement injection was stopped after obtaining a satisfying filling. The movement and sensation of the patient's lower limbs was checked immediately post-operatively. During the procedure, the operation time, intraoperative blood loss, bone cement volume and fluoroscopy times were recorded at the same time. After 6 h, all patients were allowed to wear waist brace to step around, and anti-osteoporosis drugs were prescribed and used after the operation.

### 2.3.5. Clinical evaluation

The visual analogue scale (VAS) and Oswestry Disability Index (ODI) were recorded immediately after the surgery, at 1 day, 6 months and 1 year postoperatively [35,36]. Related complications were recorded including bone cement leakage, infection, neurological damage and vertebral refracture. If a patient had vertebrae refractures during the follow-up period, VAS and ODI data would be abandoned from then on. Bone cement leakage was evaluated by postoperative CT. Leaks were classified as intervertebral, intraspinal, paravertebral and vascular leakage.

### 2.3.6. Radiological evaluation

The vertebral height and Cobb angle were measured through lateral spine X-ray [37]. Cobb angle was measured from the angle between superior and inferior endplate of targeted vertebrae. Vertebral compression rate was calculated from the ratio of anterior to posterior vertebral height. The vertebral anterior height (AH) and Cobb angle

were measured preoperatively, at 1 day and 1 year postoperatively. The bone cement distribution score was calculated based on radiographic images. The vertebral body was divided into four equal parts in anterior-posterior and lateral X-ray fluoroscopy. If bone cement taking account of more than half in each part, the score was counted as one point. Then, if the bone cement contacting the upper or/and lower endplate in the lateral position, the scores would increase one or two points. Thus the maximum score is ten [38].

2.3.7. Statistical analysis

Statistical analysis was performed using SPSS 21.0 (IBM Corp., Armonk, NY, USA). Age, BMD, BMI, serum albumin, compression rate, operation time, blood loss, AH, Cobb angle, VAS, ODI were measured and the data were recorded as mean ± standard deviations. Independent-sample t-test was used for comparison between groups and a paired-sample t-test was used for comparison within groups. The comparison of incidence rate was performed with a chi-square test. P < 0.05 indicated that the difference was statistically significant.

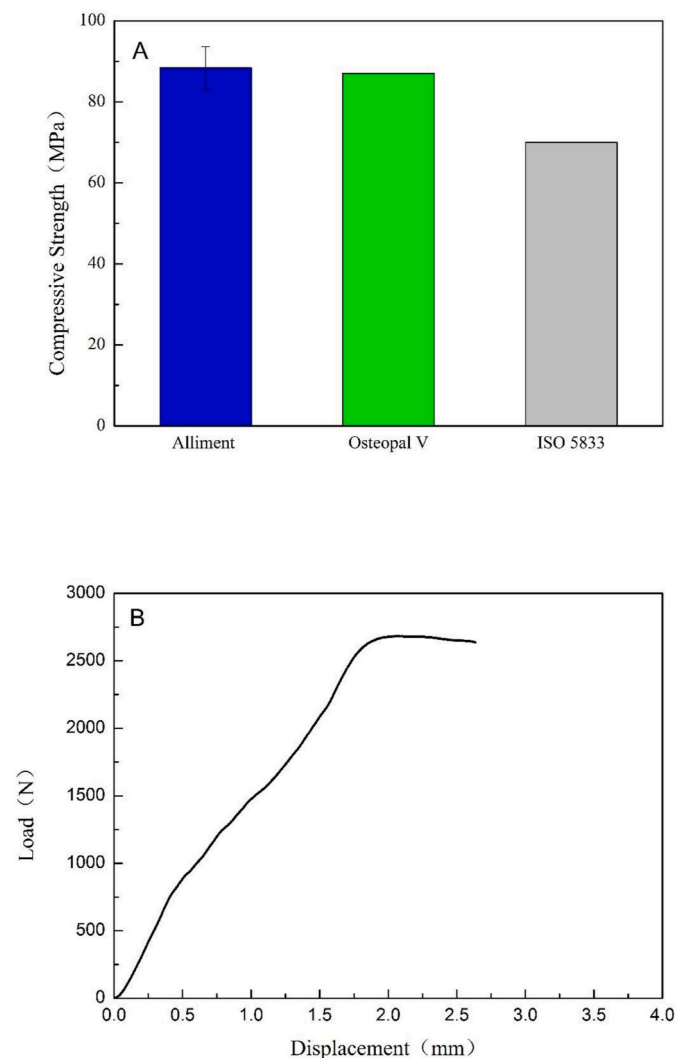


Fig. 1. Compressive strength (A) and a representative load-displacement curve of spinal ABC products and specification in ISO5833.

3. Results

3.1. Preclinical studies

3.1.1. Compressive strength

Fig. 1A and 1B show the compressive strength (88.39 ± 5.29 MPa) and a representative load-displacement curve of Alliment Cement. According to the previous report [39], the Osteopal V Cement has a compressive strength of 87 MPa, and there was no significant difference between these two kinds of bone cements (P > 0.05). In addition, the compressive strength of both products is higher than that specified by the ISO 5833 standard (not less than 70 MPa).

3.1.2. Flexural properties

Flexural strength and modulus of both Alliment Cement and Osteopal V Cement are shown in Fig. 2A–B, respectively. Alliment Cement has a flexural strength and flexural modulus of 55.58 ± 4.27 MPa and 3279.32 ± 462.61 MPa, respectively. A previous report [39] showed that the flexural strength and flexural modulus of Osteopal V Cement are 58 MPa and 3100 MPa, respectively. The comparison between the Alliment and Osteopal V Cements in terms of flexural properties suggested that they are similar. The flexural properties of both Alliment and Osteopal V Cements also meet the requirements of ISO 5833. Further statistical analysis suggested that there is no significant difference (P > 0.05) between these two kinds of cements.

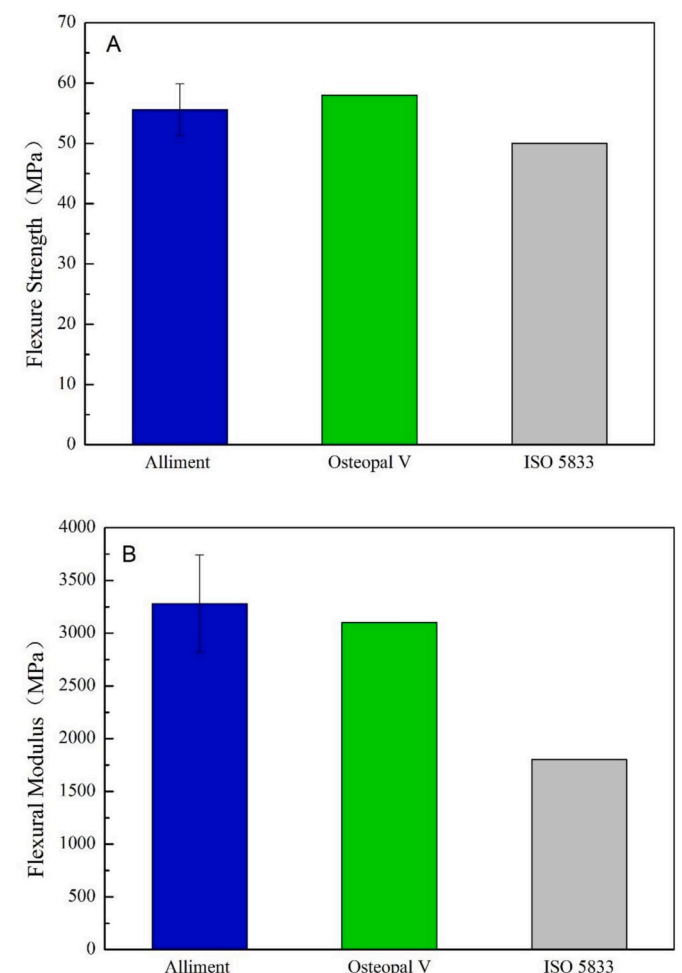


Fig. 2. The flexural properties of the spinal ABC products and specifications in ISO5833: (A) flexure strength and (B) flexural modulus.



### 3.1.3. Monomer release

Fig. 3 shows that monomer release results of Alliment Cement. The results indicate that the MMA release of both cements increases gradually overtime. After 14 d, the MMA release levels off at 305.26  $\mu\text{g/g}$  for Alliment Cement. A similar monomer release trend for Osteopal® was also reported [40].

### 3.1.4. Biocompatibility: bone implantation

The animals were in good health during the study, and there was no bleeding, redness, swelling, or ulceration on the skin at the implantation site. Through the dissection, it was found that all the samples were in place. The bone surface was intact, and no rupture was seen. In addition, no bleeding, suppuration, and neoplasms were seen around the implantation sites. Histopathological results of the implantation sites for the test (Alliment Cement) and control (UHMWPE) groups are shown in Table 1 for histological reaction scores and Fig. 4 for the representative histological images.

One week after bone implantation, a very small amount of lymphocyte infiltration was seen at the implantation sites in the test group. The wall of the fibrous capsule was thick, and there were a large area of capillary hyperplasia with fibroblast structure. The amount of surrounding bone tissue did not change significantly, as shown in Fig. 4A. A very small amount of lymphocyte infiltration was also seen at the implantation sites in the control group. The wall of the fibrous capsule is thick, with a small amount of fibroblast proliferation of capillary structure. The amount of surrounding bone tissue did not change significantly either, as shown in Fig. 4B.

Four weeks after implantation, the test group did not show much inflammatory reaction at the implantation sites. The wall of the fibrous capsule was thin, and there were a very small amount of capillary vessels. The amount of surrounding bone tissue did not change significantly, as shown in Fig. 4C. The observation in the control group is almost identical to the test group, as shown in Fig. 4D. 12 weeks after implantation, both the test and control groups presented the similar results as those evaluated at 4 weeks, as in Fig. 4E–F, respectively.

26 weeks after implantation, the test group showed a very small amount of lymphocytes and infiltration of macrophage. The wall of the fibrous capsule was very thin, and there were a very small amount of capillary vessels. The amount of surrounding bone tissue did not change significantly, as shown in Fig. 4G. The observation in the control group is almost identical to the test group, as shown in Fig. 4H.

The histological images were evaluated with reference to the method described in ISO 10993–6. After 26 weeks of implantation of the cements to the bones, the histologic results showed no tissue reactions

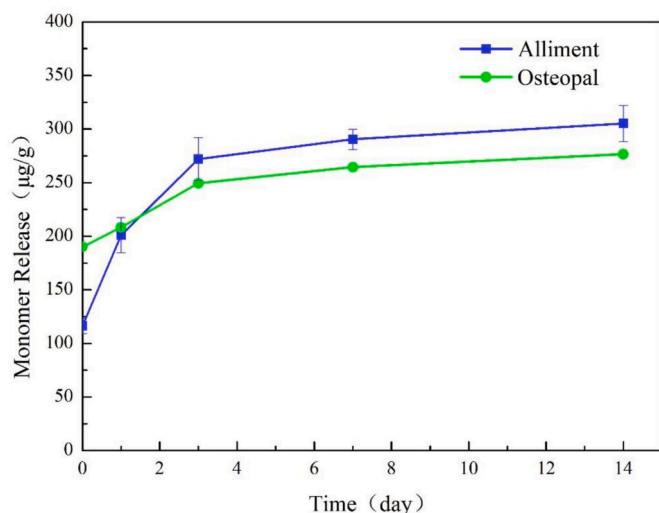


Fig. 3. MMA monomer release profiles of bone cements.

Table 1

Histopathology responses of both the test and control groups.

Observation period	Test group (Alliment®)		Control group (UHMWPE)		Average score (difference)	Response grade
	Number of implant sites/		Number of implant sites/			
	Average score	Average score	Average score	Average score		
1w	10	7.4	10	5.8	1.6	No reaction
4w	10	2.0	10	2.4	-0.4 (denoted as 0)	No reaction
12w	10	4.0	10	3.4	0.6	No reaction
26w	10	5.8	10	3.2	2.6	No reaction

surrounding the test group specimens.

### 3.1.5. Porcine cadaver study

Fig. 5 shows the procedure of the porcine cadaver test, which include building working channels and cavities (Fig. 5A and B), and mixing and injecting bone cements (Fig. 5C and D). The injected Alliment Cement was seen after dissecting the vertebrae (Fig. 5E). The results showed that the Alliment Cement in the vertebrae was cured and distributed evenly without any leakage. The cadaver study further suggested good performance of the Alliment Cement, which can be successfully used along with surgical kits for both PVP and PKP procedures.

## 3.2. Clinical investigation

A total of 30 patients were included in this study, 15 patients in group A (Alliment Cement, 24 vertebrae) and 15 patients in group B (Osteopal V Cement, 17 vertebrae). There was no significant difference in age, gender, BMD, BMI, and preoperative albumin level of patients in each group (Table 2). There was no significant difference between the two groups in vertebral compression rate, operation time, blood loss volume, bone cement volume, fluoroscopy times and bone cement distribution scores (Table 3).

### 3.2.1. Clinical evaluation

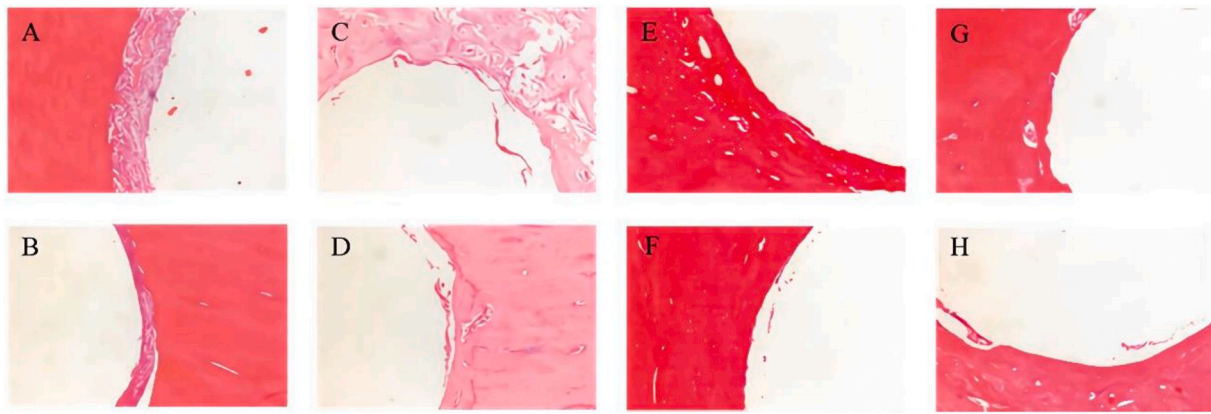
The VAS significantly reduced from  $7.53 \pm 1.19$  to  $1.73 \pm 0.7$  in group A and from  $6.93 \pm 0.96$  to  $1.67 \pm 0.49$  in group B immediately after surgery (see Fig. 6A). There was no significant difference between the two groups in VAS irrespective of preoperative ( $P = 0.14$ ) or post-operative ( $P = 0.77$ ) point. The VAS decreased in the two groups without any statistical difference irrespective of 6-month ( $P = 0.64$ ) or 1-year ( $P = 0.56$ ) follow-up.

The ODI decreased from  $79.67 \pm 4.7$  to  $33.53 \pm 4.85$  in the group A and from  $81.53 \pm 4.94$  to  $36.73 \pm 5.07$  in group B immediately after surgery (see Fig. 6B). There was no significant difference between the two groups in ODI irrespective of preoperative ( $P = 0.30$ ) or post-operative ( $P = 0.09$ ) point. The ODI decreased in the two groups without any statistical difference irrespective of 6-month ( $P = 0.06$ ) or 1-year follow-up ( $P = 0.85$ ).

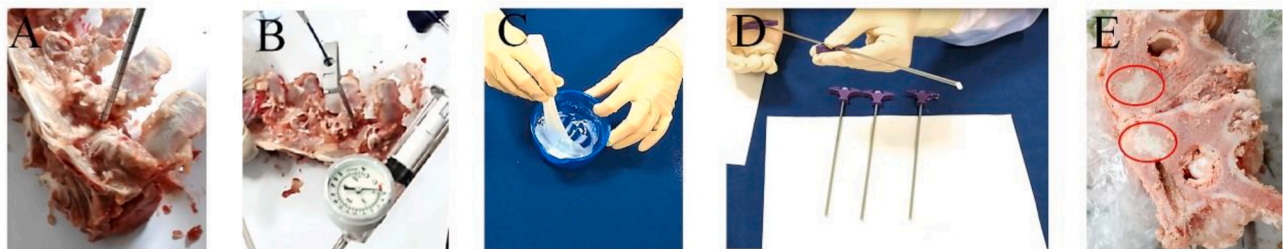### 3.2.2. Radiological evaluation

The AH increased from preoperative ( $2.12 \pm 0.56$ ) cm to post-operative ( $2.42 \pm 0.50$ ) cm in group A ( $P < 0.05$ ) and from preoperative ( $2.06 \pm 0.46$ ) cm to postoperative ( $2.5 \pm 0.45$ ) cm in group B ( $P < 0.05$ ), without any statistical difference between the two groups irrespective of preoperative ( $P = 0.73$ ) or postoperative ( $P = 0.59$ ) point (see Fig. 6C). Moreover, the AH can maintain at ( $2.24 \pm 0.56$ ) cm in group A and ( $2.19 \pm 0.43$ ) cm in group B after 1-year follow-up without any statistical difference between the two groups ( $P = 0.78$ ).

The Cobb angle significantly decreased from preoperative ( $9.62 \pm 5.86$ )° to postoperative ( $6.94 \pm 5.36$ )° in group A ( $P < 0.05$ ) and from



**Fig. 4.** Histological images of the test group (Alliment®) and the control (implantable UHMWPE) after bone implantation: wherein A, C, E and G are the test group after 1, 4, 12 and 26 weeks, respectively; B, D, F and H are the control group after 1, 4, 12 and 26 weeks, respectively (Image magnification: 100 ×).



**Fig. 5.** Porcine cadaver study: (A) Establishment of a working cannula, (B) Creation of bony cavity with a balloon bone tamp, (C) Mixing of bone cement, (D) Injection of bone cements and (E) Dissected porcine cadaver vertebrae, which demonstrated the even distribution of Alliment® spinal bone cement (see circles in red). (For interpretation of the references to color in this figure legend, the reader is referred to the Web version of this article.)

**Table 2**

Preoperative basic information of the two groups.

	Group A (Alliment®)	Group B (Osteopal® V)	P
Patients No	15	15	1
Age (year)	73.67 ± 8.95	71.4 ± 8.30	0.4781
Sex (M:F)	3:12	3:12	1
BMD(T)	2.6 ± 0.68	2.57 ± 1.19	0.8381
BMI(kg/m <sup>2</sup> )	24.48 ± 4.52	23.50 ± 3.53	0.5121
ALB	36.29 ± 3.65	37.13 ± 3.60	0.5342

**Table 3**

Perioperative information of the two groups of patients.

	Group A (Alliment®)	Group B (Osteopal® V)	P
Vertebrae No	24	17	
Compression rate(%)	72.57 ± 1.82	79.59 ± 12.59	0.1251
Operative time(min)	45.07 ± 20.97	38.67 ± 17.67	0.3738
Blood loss volume(ml)	6.13 ± 2.53	6.6 ± 2.56	0.6195
Bone cement volume(ml)	4.21 ± 0.39	4.13 ± 1.17	0.5864
Fluoroscopy times	20.2 ± 4.18	19.07 ± 2.89	0.3949
PMMA distribution score	7.75 ± 1.07	7.18 ± 1.55	0.1689
Bone cement leakage	6	4	1
Vertebrae refracture	2	2	1

preoperative ( $10.28 \pm 5.52$ )° to postoperative ( $7.82 \pm 5.28$ )° in group B ( $P < 0.05$ ), without any statistical difference between the two groups irrespective of preoperative ( $P = 0.72$ ) or postoperative ( $P = 0.61$ ) point. Moreover, the Cobb angle can maintain at ( $7.53 \pm 5.2$ )° in group A and ( $8.65 \pm 5.36$ )° in group B after 1-year follow-up without any statistical difference between the two groups ( $P = 0.51$ ) (see Fig. 6D). Moreover, bone cement distribution scores in the two groups did not have a

significant difference ( $P = 0.17$ ).

A representative case of group A (the Alliment Cement) is presented in Fig. 7. A 57 year-old female was diagnosed as OVCF in L2 and L3 due to an incidental fall. A PVP was performed, in consideration of refractory back pain after several weeks' conservative treatment. The detailed process of filling the bone cement was presented. Immediately after the surgery, the patient felt significant relief from back pain.

Another representative case of group A is presented in Fig. 8. A 73 year-old female underwent PVP due to OVCF (T8) a couple of years ago. An accidental fall caused fresh OVCF (T5). PVP was performed in T5 with the Alliment Cement. The vertebra morphology and height in radiographic images at preoperative and postoperative follow-up points were presented in Fig. 8. Immediately after the surgery, the back pain was significantly alleviated. The patient was able to walk with a waist brace one day after the operation and was discharged. After strict anti-osteoporosis drug treatments, the patient did not experience any new fracture within one-year follow-up.

### 3.2.3. Complications

Postoperative CT showed leakage of bone cement in six vertebrae in group A (four intervertebral and two paravertebral leakages) and four vertebrae in group B (two intervertebral and two paravertebral leakages) which didn't result in clinical symptoms. Moreover, two patients in each group experienced vertebral refractures within 1-year follow-up. Four refractured patients had PVP procedures again which resulted in immediate pain relief postoperatively. Besides, there were no serious complications such as spinal cord compression, nerve root damage, pulmonary embolism, thrombus or wound infection observed in our study.

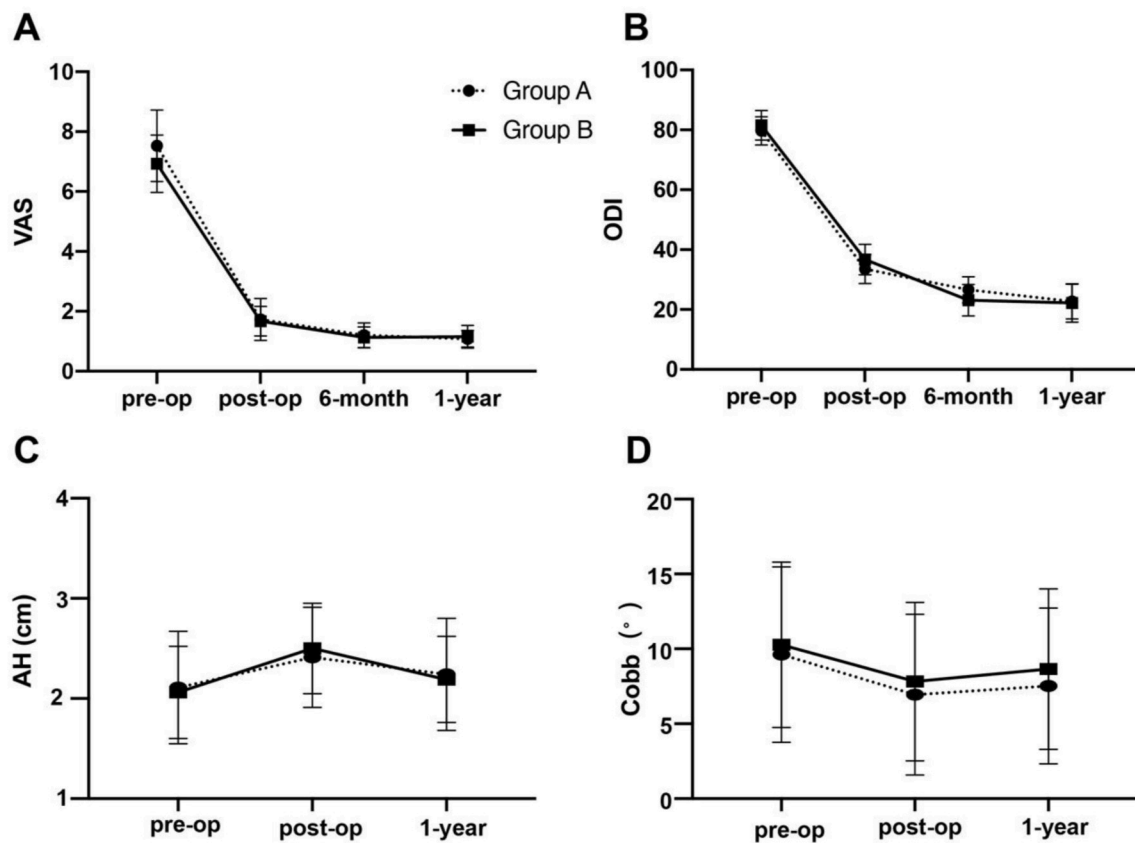


Fig. 6. The comparison and variation trend between two groups in clinical and radiological evaluation. Figure A and B showed a significant decrease in VAS and ODI after surgery in both groups. Figure C showed a similar variation trend in AH between group A and group B. Figure D demonstrated a similar variation trend in Cobb's angle between group A and group B.

#### 4. Discussion

This study aimed to report the translational research and evaluate the safety and efficacy of the first NMPA-approved Chinese spinal ABC product as compared with a German bone cement. PVP has been widely used in the treatment of osteoporotic vertebral compression fractures since it was first reported in 1987 [41]. After the injection of bone cement, PVP can promptly stabilize the vertebral body, relieve pain, and achieve good clinical efficacy [42]. Both PVP and PKP procedures were introduced to China in the early 2000s along with the commercialization of domestic surgical instruments. However, before 2019, spinal ABCs used in Chinese market were all imported spinal ABCs. With the successful research, development, manufacturing, regulatory approval and clinical applications of domestic spinal bone cements for both PVP and PKP, Chinese spinal ABC products are expected to gradually expand its market share and clinical usage.

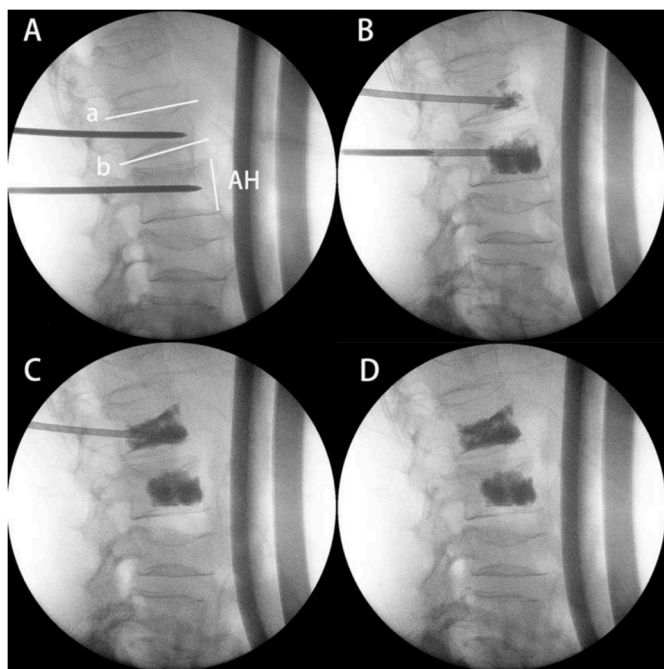
The goal of translational research is to translate the discoveries of basic and applied research (i.e., bench) to clinical practice (i.e., bedside) through the development and commercialization of medical products, which could benefit human healthcare. Translation of spinal ABCs serves as a classical example. Such translation should start with real user needs or questions which include, but not limited to, clinical needs. In order to solve the specific need or question, a regulated design control process should be followed [43]. During the design process, the roadmap should always focus on satisfying the user needs and solving the question through both design verification and validation. If the translation of a biomaterial product is not needs/questions-centered, but only material-focused, it may not lead to useful final products. The current study focuses on the need of developing Chinese spinal ABCs. A thorough product design control process was executed including both design verification such as mechanical and monomer release tests and design

validation of porcine cadaver study and clinical investigation.

Spinal ABCs are used to fill vertebral compression fractures. The application of spinal ABCs has demonstrated to alleviate pain in patients clinically [10,44]. In order to prevent further collapse and deformation of the vertebral body, the spinal ABCs must have appropriate mechanical properties to maintain or restore the vertebral stability in the body. The mechanical properties of spinal ABCs should be close to that of natural bone. The strength of spinal ABCs must be able to maintain and undertake the mechanical strength of the vertebral body permanently. If the applied load in the body through vertebral column is higher than the strength of the spinal ABCs, the cement is likely to break, which may cause secondary damages to the patients. Thus, the mechanical properties are very important for the clinical application of spinal ABCs. The compressive and flexural strengths of Alliment Cement are similar to those of Osteopal V Cement that have been clinically used for a long time, and in between the theoretical mechanical strength of cortical and cancellous bone [45,46], which demonstrates that the Alliment Cement has mechanical properties required for its application to stabilize the vertebral compression fractures.

The curing of ABCs is achieved by the polymerization of MMA [47]. With the increase of monomer conversion rate during the free radical polymerization of MMA, the viscosity of the liquid-powder system of curing cement increases, which affects the movement of the monomer in the system and the monomer conversion cannot reach to 100%. According to the literature [32], the percentage of residual monomers to its original total amount after curing ABCs is typically between 2% and 6%. Based on a previously published report [32], the monomer release of various commercial ABCs is typically below 450  $\mu\text{g/g}$ . These commercial cements have been on the market for many years with demonstrated safety and effectiveness. The monomer release results of Alliment Cement are in compliance with the reported value. As a result, the





**Fig. 7.** A 57 year-old female underwent PVP in L2 and L3. The operative fluoroscopy presented the detailed process of filling the Alliment® spinal bone cement. A. Insertion of the puncture needles to L2 and L3 vertebrae. B. Injection of bone cements. C. Satisfactory filling and pulling out the working cannula. D. Uniform distribution of bone cements without leakage. Anterior height (AH) is measured from the anterior superior margin to anterior inferior margin of the vertebral body. The Cobbs angle is defined as the angle between the superior endplate line (a) and the inferior endplate line (b).

Alliment Cement is as safe as other commercial ABCs from the perspective of monomer release.

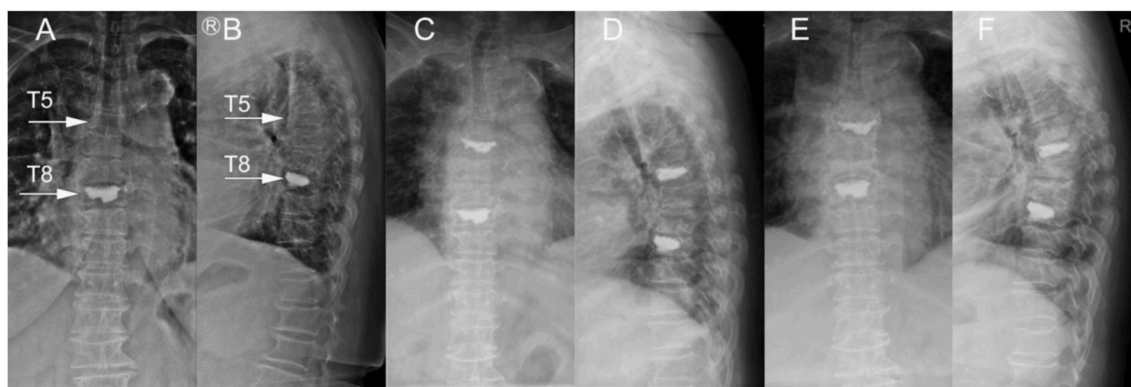
Biocompatibility of spinal ABCs was evaluated by conducting a battery of standard tests and results showed the product is biocompatible. The potential biocompatibility concerns of ABCs are related to MMA toxicity, the heat generated during cement curing and cement particulates after curing. MMA can permeate human blood. High-concentration MMA not only has the adverse effects of inhibiting the myocardium, but also destroys granulocytes, monocytes and endothelial cells in the blood, causing them to release proteolytic enzymes to induce cell and tissue lysis. MMA can also act on the calcium channels of vascular smooth muscle, leading to vasodilation, slow blood flow, and blood pressure drop [48]. A study also found that after 4 ml of an ABC

was injected into the vertebral body in an in vivo animal model, the peak temperature of cement in the center of vertebrae was 58 °C and the period above 50 °C lasted for 1 min [49]. Previous studies reported that bone cells and bone morphogenetic proteins can tolerate 60 °C for 30min and maintain their vitality [50], and the histological damage of nerve fibers appears at 60 °C–70 °C [51]. ABC particles can cause embolism after entering the blood circulation system [52,53]. Confirmed embolic contents include fat, bone marrow, bone cement, air, bone particles, aggregates of platelets and fibrin [52,53]. These emboli may embolize the lungs, heart, and/or coronary arteries. A large number of small pulmonary emboli are thought to be the characteristics of bone cement implantation syndrome (BCIS) which can cause hypoxia and insufficiency of heart functions, and then leading to hypotension. As a result, close clinical attentions should be paid to reduce MMA exposure, heat generation and cement particulates in order to ensure the safety of ABC products.

Design validation of a medical device can be performed via different methods including saw-bone lab, cadaver test, animal study and clinical trial. Although human cadaver tests of spinal ABCs were reported, animal cadavers provide an easy, economic and efficient method to validate the product design. Porcine was identified in this study because of the quality of bone tissues. The porcine cadaver results of this study demonstrated feasibility of performing PVP and PKP procedures with Alliment Cement in combination with marketed surgical instruments.

As described in previous literature, the stabilization of the vertebral body was the most important mechanism of relieving pain which mainly depended on interlocking effect between bone cement and bone trabeculae [54]. Reports have shown that the viscosity of spinal ABCs may have an impact on its clinical outcome. Miao et al. reported that a low-viscosity spinal ABC has better flow properties than that of high viscosity spinal ABC, thus low viscosity cement can be closely connected with more bone structure under lower pressure [55]. Wang et al. reported that the viscosity of bone cement can be adjusted based on the working time. The viscosity of bone cement can also vary with the temperature of the operating room [56]. Some surgeons preferred to inject bone cement during the early stage of the working phase with potential better diffusion to vertebrae [57]. In our present study, a medium-viscosity Alliment Cement was compared to a high-viscosity Osteopal V Cement, but no significant clinical difference was found between these two kinds of cements in the aspects of relieving pain and improving the quality of life. The Alliment Cement has achieved similar clinical benefits as Osteopal V Cement.

The AH and Cobb angle were improved compared with preoperative data in both the Alliment and Osteopal V groups in this study. The improvement of AH and Cobb angle were benefited from reinforcement and stabilization effects of injected bone cements on damaged vertebral



**Fig. 8.** A 73 year-old female underwent PVP for a vertebral compression fracture (T8) two years ago. An accidental fall caused a fresh vertebral compression fracture (T5). PVP was performed in T5 with the Alliment® spinal bone cement. A & B. Preoperative T5 vertebra morphology and height in the anterior-posterior and lateral X-rays, respectively. C & D. Immediate postoperative vertebra morphology and height in the anterior-posterior and lateral X-rays, respectively. E & F. 1-year postoperative vertebra morphology and height in the anterior-posterior and lateral X-rays, respectively.



bodies [55,58]. At 1-year follow-up, both groups did not present significant loss in terms of vertebral height comparing with that preoperatively. Meanwhile, there was no remarkable difference in the operation time, blood loss and fluoroscopy frequencies. In addition, compared to the Osteopal V Cement, the applications of the Alliment Cement did not increase difficulties for surgical operations and the related radiation risks.

The main complication of PVP was the bone cement leakage. The incidence of cement leakage in PVP was reported as high as 63% [59]. However, most patients who experienced bone cement leakage would not result in neurological symptom, only 1% of cement leakage patients may require surgical intervention [60]. Previous studies have shown that the viscosity of spinal ABCs may affect the rate of cement leakage [61–63]. Baroud demonstrated that cement leakage rate will decrease from 50% to 10% when the viscosity of cement increased from low to medium [64]. However, Breusch also showed that high-viscosity cement may increase rate of fat embolisms because of uneven high pressure distribution when the cement was applied [65]. In our present study, we did not find any difference in leakage rate and fat embolisms between the two kinds of bone cements. Vertebrae refractures could be a complication related to cement leakage, due to increased local stress [66]. In one-year follow-up of this study, there was no significant difference in the incidence of the vertebrae refracture between the two groups.

## 5. Conclusion

The bench-to-bed research of the first NMPA-approved Chinese spinal bone cement product (Alliment Cement) confirmed that the translation of biomaterials products must follow the identified user needs and regulated design control processes. Comparing with another commercial product (Osteopal V Cement) that has been marketed for years, Alliment Cement has comparable mechanical properties as well as monomer release profile. Standardized biocompatibility bone implantation tests also showed good biocompatibility of the Alliment Cement. Porcine cadaver study further validated the performance of the product for both PVP and PKP procedures. Most importantly, a retrospective clinical investigation demonstrated the safety and efficacy of the Alliment Cement in comparison with the Osteopal V Cement.

## Declaration of competing interest

Xuan Wang, Hongwei Zhang and Hongtao Nie work for the manufacturer of Alliment Cement. Other authors declare no conflict of interest.

## CRediT authorship contribution statement

**Fei Feng:** Data curation, Investigation, Validation, Writing – original draft. **Mengmeng Chen:** Data curation, Formal analysis, Validation, Writing – original draft. **Xuan Wang:** Data curation, Validation, Writing – original draft. **Hongwei Zhang:** Data curation, Validation. **Hongtao Nie:** Conceptualization, Methodology, Supervision, Writing – review & editing. **Hai Tang:** Conceptualization, Methodology, Supervision, Writing – review & editing.

## References

- D.C. Smith, The genesis and evolution of acrylic bone cement, *Orthop Clin North Am* 36 (2005) 1–10, <https://doi.org/10.1016/j.oct.2004.06.012>.
- D. Wirz, A.U. Daniels, B. Gopfert, E.W. Morscher, Clinical development and current status: Europe, *Orthop Clin North Am* 36 (2005) 63–73, <https://doi.org/10.1016/j.oct.2004.07.002>, vi.
- R.C. Johnston, Acrylic bone cement: clinical development and current status in North America, *Orthop Clin North Am* 36 (2005) 75–84, <https://doi.org/10.1016/j.oct.2004.06.005>, vii.
- G. Lewis, Alternative acrylic bone cement formulations for cemented arthroplasties: present status, key issues, and future prospects, *J Biomed Mater Res B Appl Biomater* 84 (2008) 301–319, <https://doi.org/10.1002/jbm.b.30873>.
- G. Lewis, Properties of acrylic bone cement: state of the art review, *J Biomed Mater Res* 38 (1997) 155–182, [10.1002/\(sici\)1097-4636\(199722\)38:2<155::aid-jbm10>3.0.co;2-c](https://doi.org/10.1002/(sici)1097-4636(199722)38:2<155::aid-jbm10>3.0.co;2-c).
- G. Lewis, Viscoelastic properties of injectable bone cements for orthopaedic applications: state-of-the-art review, *J Biomed Mater Res B Appl Biomater* 98 (2011) 171–191, <https://doi.org/10.1002/jbm.b.31835>.
- G. Lewis, Fatigue testing and performance of acrylic bone-cement materials: state-of-the-art review, *J Biomed Mater Res B Appl Biomater* 66 (2003) 457–486, <https://doi.org/10.1002/jbm.b.10018>.
- G. Lewis, J.S. Nyman, Toward standardization of methods of determination of fracture properties of acrylic bone cement and statistical analysis of test results, *J Biomed Mater Res* 53 (2000) 748–768, [10.1002/1097-4636\(2000\)53:6<748::aid-jbm18>3.0.co;2-z](https://doi.org/10.1002/1097-4636(2000)53:6<748::aid-jbm18>3.0.co;2-z).
- K.D. Kuehn, W. Ege, U. Gopp, Acrylic bone cements: composition and properties, *Orthop Clin North Am* 36 (2005) 17–28, <https://doi.org/10.1016/j.oct.2004.06.010>.
- K.D. Kuehn, W. Ege, U. Gopp, Acrylic bone cements: mechanical and physical properties, *Orthop Clin North Am* 36 (2005) 29–39, <https://doi.org/10.1016/j.oct.2004.06.011>, v-vi.
- S.M. Kenny, M. Buggy, Bone cements and fillers: a review, *J Mater Sci Mater Med* 14 (2003) 923–938, <https://doi.org/10.1023/a:1026394530192>.
- E.J. Harper, W. Bonfield, Tensile characteristics of ten commercial acrylic bone cements, *J Biomed Mater Res* 53 (2000) 605–616, [https://doi.org/10.1002/1097-4636\(200009\)53:5<605::aid-jbm22>3.0.co;2-5](https://doi.org/10.1002/1097-4636(200009)53:5<605::aid-jbm22>3.0.co;2-5).
- G. Lewis, Properties of antibiotic-loaded acrylic bone cements for use in cemented arthroplasties: a state-of-the-art review, *J Biomed Mater Res B Appl Biomater* 89 (2009) 558–574, <https://doi.org/10.1002/jbm.b.31220>.
- J.G. Hendriks, J.R. van Horn, H.C. van der Mei, H.J. Busscher, Backgrounds of antibiotic-loaded bone cement and prosthesis-related infection, *Biomaterials* 25 (2004) 545–556, [https://doi.org/10.1016/s0142-9612\(03\)00554-4](https://doi.org/10.1016/s0142-9612(03)00554-4).
- G. Lewis, S. Janna, A. Bhattaram, Influence of the method of blending an antibiotic powder with an acrylic bone cement powder on physical, mechanical, and thermal properties of the cured cement, *Biomaterials* 26 (2005) 4317–4325, <https://doi.org/10.1016/j.biomaterials.2004.11.003>.
- T. Russo, A. Gloria, R. De Santis, U. D'Amora, G. Balato, A. Vollaro, O. Oliviero, G. Improta, M. Triassi, L. Ambrosio, Preliminary focus on the mechanical and antibacterial activity of a PMMA-based bone cement loaded with gold nanoparticles, *Bioact Mater* 2 (2017) 156–161, <https://doi.org/10.1016/j.bioactmat.2017.05.002>.
- D.K. Mills, U. Jammalamadaka, K. Tappa, J. Weisman, Studies on the cytocompatibility, mechanical and antimicrobial properties of 3D printed poly (methyl methacrylate) beads, *Bioact Mater* 3 (2018) 157–166, <https://doi.org/10.1016/j.bioactmat.2018.01.006>.
- S.S. Jameson, A. Asaad, M. Diamant, A. Kasim, T. Bigirumurame, P. Baker, J. Mason, P. Partington, M. Reed, Antibiotic-loaded bone cement is associated with a lower risk of revision following primary cemented total knee arthroplasty: an analysis of 731,214 cases using National Joint Registry data, *Bone Joint J* 101-B (2019) 1331–1347, <https://doi.org/10.1302/0301-620X.101B11.BJJ-2019-0196.R1>.
- G. Lewis, Injectable bone cements for use in vertebroplasty and kyphoplasty: state-of-the-art review, *J Biomed Mater Res B Appl Biomater* 76 (2006) 456–468, <https://doi.org/10.1002/jbm.b.30398>.
- M.J. Provenzano, K.P. Murphy, L.H. Riley 3rd, Bone cements: review of their physicochemical and biochemical properties in percutaneous vertebroplasty, *AJNR Am J Neuroradiol* 25 (2004) 1286–1290.
- I.H. Lieberman, D. Togawa, M.M. Kayanja, Vertebroplasty and kyphoplasty: filler materials, *Spine J* 5 (2005) 305S–316S, <https://doi.org/10.1016/j.spinee.2005.02.020>.
- S.D. Badilatti, G.A. Kuhn, S.J. Ferguson, R. Muller, Computational modelling of bone augmentation in the spine, *J Orthop Translat* 3 (2015) 185–196, <https://doi.org/10.1016/j.jot.2015.09.003>.
- M.P. Bostrom, J.M. Lane, Future directions Augmentation of osteoporotic vertebral bodies, *Spine (Phila Pa)* 22 (1976) 38S–42S, <https://doi.org/10.1097/00007632-199712151-00007>, 1997.
- M.A. Liebschner, W.S. Rosenberg, T.M. Keaveny, Effects of bone cement volume and distribution on vertebral stiffness after vertebroplasty, *Spine (Phila Pa)* 26 (1976) 1547–1554, <https://doi.org/10.1097/00007632-200107150-00009>, 2001.
- F. McKiernan, T. Faciszewski, R. Jensen, Reporting height restoration in vertebral compression fractures, *Spine (Phila Pa)* 28 (1976) 2517–2521, discussion 3. [10.1097/01.BRS.0000092424.29886.C9](https://doi.org/10.1097/01.BRS.0000092424.29886.C9), 2003.
- P.L. Lai, L.H. Chen, W.J. Chen, I.M. Chu, Chemical and physical properties of bone cement for vertebroplasty, *Biomed J* 36 (2013) 162–167, <https://doi.org/10.4103/2319-4170.112750>.
- Z. He, Q. Zhai, M. Hu, C. Cao, J. Wang, H. Yang, B. Li, Bone cements for percutaneous vertebroplasty and balloon kyphoplasty: current status and future developments, *J Orthop Translat* 3 (2015) 1–11, <https://doi.org/10.1016/j.jot.2014.11.002>.
- G.A. Aitchison, D.W. Hukins, J.J. Parry, D.E. Shepherd, S.G. Trotman, A review of the design process for implantable orthopedic medical devices, *Open Biomed Eng J* 3 (2009) 21–27, <https://doi.org/10.2174/187412070903010021>.
- Heraeus, OSTEOPAL® - bone cements for augmentation of vertebral bodies : Instructions for use, June Available from: URL: <https://www.heraeus.com/en/hme>

- /products/solutions/heraeus\_medical/spinal\_augmentation/osteopal\_vertebral\_compression\_fractures.html, 2021.
- [30] ISO, Implants for surgery — acrylic resin cements, Online (2021 June). Available from: URL: <https://www.iso.org/standard/30980.html>, 2002. ISO 5833.
- [31] ASTM, ASTM F451-16:standard specification for acrylic bone cement, Online, June. Available from: URL: <https://www.astm.org/DATABASE.CART/HISTORICAL/F451-16.html>, 2021.
- [32] K.-D. Kühn, *Bone Cements*[M], 2000, pp. 247–252.
- [33] ISO, Biological evaluation of medical devices - Part 6: tests for local effects after implantation, Online (2021 June). Available from: URL: <https://www.iso.org/standard/61089.html>, 2016. ISO 10993-6.
- [34] P. Korovessis, K. Vardakastanis, V. Vitsas, V. Syrimpeis, Is Kiva implant advantageous to balloon kyphoplasty in treating osteolytic metastasis to the spine? Comparison of 2 percutaneous minimal invasive spine techniques: a prospective randomized controlled short-term study, *Spine (Phila Pa 39 (1976) E231–E239)*, <https://doi.org/10.1097/BRS.000000000000112>, 2014.
- [35] J.C. Fairbank, P.B. Pynsent, The Oswestry disability index, *Spine Phila Pa 25 (1976) 2940–2952*, <https://doi.org/10.1097/00007632-200011150-00017>, discussion 2952, 2000.
- [36] H.M. McCormack, D.J. Horne, S. Sheather, Clinical applications of visual analogue scales: a critical review, *Psychol Med 18 (1988) 1007–1019*, <https://doi.org/10.1017/s0033291700009934>.
- [37] M. Chen, R. Wang, P. Jia, L. Bao, H. Tang, Stentoplasty with resorbable calcium salt bone void fillers for the treatment of vertebral compression fracture: evaluation after 3 years, *Clin Interv Aging 16 (2021) 843–852*, <https://doi.org/10.2147/CIA.S308667>.
- [38] J. Liu, J. Tang, H. Liu, Z. Gu, Y. Zhang, S. Yu, A novel and convenient method to evaluate bone cement distribution following percutaneous vertebral augmentation, *Sci Rep 10 (2020) 16320*, <https://doi.org/10.1038/s41598-020-73513-2>.
- [39] Heraeus, OSTEOPAL® - bone cements for augmentation of vertebral bodies: Mechanical properties, June Available from: URL: <http://gushuini.com/product/detail.php?id=4>, 2021.
- [40] K.-D. Kühn, *Bone Cements*[M], 2000, pp. 95–99.
- [41] P. Galibert, H. Deramond, P. Rosat, D. Le Gars, [Preliminary note on the treatment of vertebral angioma by percutaneous acrylic vertebroplasty], *Neurochirurgie 33 (1987) 166–168*.
- [42] A.J. Evans, M.E. Jensen, K.E. Kip, A.J. DeNardo, G.J. Lawler, G.A. Negin, K. B. Remley, S.M. Boutin, S.A. Dunnagan, Vertebral compression fractures: pain reduction and improvement in functional mobility after percutaneous polymethylmethacrylate vertebroplasty retrospective report of 245 cases, *Radiology 226 (2003) 366–372*, <https://doi.org/10.1148/radiol.2262010906>.
- [43] Y. Sun, H. Wu, W. Wang, R. Zan, H. Peng, S. Zhang, X. Zhang, Translational status of biomedical Mg devices in China, *Bioact Mater 4 (2019) 358–365*, <https://doi.org/10.1016/j.bioactmat.2019.11.001>.
- [44] G. Marcucci, M.L. Brandi, Kyphoplasty and vertebroplasty in the management of osteoporosis with subsequent vertebral compression fractures, *Clin Cases Miner Bone Metab 7 (2010) 51–60*.
- [45] J. Tong, K.Y. Wong, C. Lupton, Determination of interfacial fracture toughness of bone-cement interface using sandwich Brazilian disks, *Eng Fract Mech 74 (2007) 1904–1916*, <https://doi.org/10.1016/j.engfracmech.2006.02.014>.
- [46] S. Saha, S. Pal, Mechanical properties of bone cement: a review, *J Biomed Mater Res 18 (1984) 435–462*, <https://doi.org/10.1002/jbm.820180411>.
- [47] U.Y. Karatepe, T. Ozdemir, Improving mechanical and antibacterial properties of PMMA via polyblend electrospinning with silk fibroin and polyethyleneimine towards dental applications, *Bioact Mater 5 (2020) 510–515*, <https://doi.org/10.1016/j.bioactmat.2020.04.005>.
- [48] H.E. Romeo, M.A. Fanovich, Synthesis of tetracalcium phosphate from mechanochemically activated reactants and assessment as a component of bone cements, *J Mater Sci Mater Med 19 (2008) 2751–2760*, <https://doi.org/10.1007/s10856-008-3403-8>.
- [49] N. Aebli, B.G. Goss, P. Thorpe, R. Williams, J. Krebs, *Vivo* temperature profile of intervertebral discs and vertebral endplates during vertebroplasty: an experimental study in sheep, *Spine (Phila Pa 31 (1976) 1674–1678)*, discussion 1679. [10.1097/01.brs.0000224193.52587.d8](https://doi.org/10.1097/01.brs.0000224193.52587.d8).
- [50] Y. Hu, J. Wang, S. Lu, The effects of microwave heating on osteoinduction of demineralized bone matrix in rabbits, *Zhonghua Wai Ke Za Zhi 35 (1997) 564–567*.
- [51] S. Konno, K. Olmarker, G. Byrod, C. Nordborg, B. Stromqvist, B. Rydevik, The European Spine Society AcroMed Prize 1994. Acute thermal nerve root injury, *Eur Spine J 3 (1994) 299–302*, <https://doi.org/10.1007/BF02200140>.
- [52] A.J. Donaldson, H.E. Thomson, N.J. Harper, N.W. Kenny, Bone cement implantation syndrome, *Br J Anaesth 102 (2009) 12–22*, <https://doi.org/10.1093/bja/aen328>.
- [53] N.D. Lafont, M.K. Kalonji, J. Barre, C. Guillaume, J.G. Boogaerts, Clinical features and echocardiography of embolism during cemented hip arthroplasty, *Can J Anaesth 44 (1997) 112–117*, <https://doi.org/10.1007/BF03012997>.
- [54] F.E. McKiernan, Kyphoplasty and vertebroplasty: how good is the evidence? *Curr Rheumatol Rep 9 (2007) 57–65*, <https://doi.org/10.1007/s11926-007-0023-0>.
- [55] F. Miao, X. Zeng, W. Wang, Z. Zhao, Percutaneous vertebroplasty with high- versus low-viscosity bone cement for osteoporotic vertebral compression fractures, *J Orthop Surg Res 15 (2020) 302*, <https://doi.org/10.1186/s13018-020-01835-y>.
- [56] M. Wang, Q. Jin, High-viscosity bone cement for vertebral compression fractures: a prospective study on intravertebral diffusion and leakage of bone cement, *BMC Musculoskelet Disord 21 (2020) 589*, <https://doi.org/10.1186/s12891-020-03613-7>.
- [57] G. Baroud, M. Samara, T. Steffen, Influence of mixing method on the cement temperature-mixing time history and doughing time of three acrylic cements for vertebroplasty, *J Biomed Mater Res B Appl Biomater 68 (2004) 112–116*, <https://doi.org/10.1002/jbm.b.20009>.
- [58] K. Sun, Y. Liu, H. Peng, J.F. Tan, M. Zhang, X.N. Zheng, F.Z. Chen, M.H. Li, A comparative study of high-viscosity cement percutaneous vertebroplasty vs. low-viscosity cement percutaneous kyphoplasty for treatment of osteoporotic vertebral compression fractures, *J Huazhong Univ Sci Technolog Med Sci 36 (2016) 389–394*, <https://doi.org/10.1007/s11596-016-1597-4>.
- [59] M.J. Nieuwenhuijse, A.R. Van Erkel, P.D. Dijkstra, Cement leakage in percutaneous vertebroplasty for osteoporotic vertebral compression fractures: identification of risk factors, *Spine J 11 (2011) 839–848*, <https://doi.org/10.1016/j.spinee.2011.07.027>.
- [60] J.K. Chen, H.M. Lee, J.T. Shih, S.T. Hung, Combined extraforaminal and intradiscal cement leakage following percutaneous vertebroplasty, *Spine (Phila Pa 32 (1976) E358–E362)*, <https://doi.org/10.1097/BRS.0b013e31805c0b25>, 2007.
- [61] L. Zhang, J. Wang, X. Peng, Y. Tao, J. Yang, Y. Wang, S. Zhang, J. Cai, J. Huang, A comparison of high viscosity bone cement and low viscosity bone cement vertebroplasty for severe osteoporotic vertebral compression fractures, *Clin Neurol Neurosurg 129 (2015) 10–16*, <https://doi.org/10.1016/j.clineuro.2014.11.018>.
- [62] R. Lador, S. Liberman, P. Ben-Galim, N. Dreiangel, C.A. Reitman, J.A. Hipp, A cadaver study to compare vertebral augmentation with a high-viscosity cement to augmentation with conventional lower-viscosity cement, *J Spinal Disord Tech 26 (2013) 68–73*, <https://doi.org/10.1097/BSD.0b013e3182337d69>.
- [63] Z.F. Zhang, J.L. Yang, H.C. Jiang, Z. Lai, F. Wu, Y.Q. Pan, Z.X. Liu, An updated comparison of high- and low-viscosity cement vertebroplasty in the treatment of osteoporotic thoracolumbar vertebral compression fractures: a retrospective cohort study, *Int J Surg 43 (2017) 126–130*, <https://doi.org/10.1016/j.ijssu.2017.05.067>.
- [64] G. Baroud, M. Crookshank, M. Bohner, High-viscosity cement significantly enhances uniformity of cement filling in vertebroplasty: an experimental model and study on cement leakage, *Spine (Phila Pa 31 (1976) 2562–2568)*, <https://doi.org/10.1097/01.brs.0000240695.58651.62>, 2006.
- [65] S. Breusch, C. Heisel, J. Muller, T. Borchers, H. Mau, Influence of cement viscosity on cement interdigitation and venous fat content under in vivo conditions: a bilateral study of 13 sheep, *Acta Orthop Scand 73 (2002) 409–415*, <https://doi.org/10.1080/00016470216320>.
- [66] E.P. Lin, S. Ekholm, A. Hiwatashi, P.L. Westesson, Vertebroplasty: cement leakage into the disc increases the risk of new fracture of adjacent vertebral body, *AJNR Am J Neuroradiol 25 (2004) 175–180*.